

Zoological Society RADIOLGY CONSULTING SERVICE

TURTLE

Report Number: M
Gender: M
Study Date: 20200405
Accession: 8Y
Age: 8Y
Submitted By: 4/7/2020 5:49:30 PM UTC
Anesthesia Used: No
Submitted: 4/5/2020 7:37:00 PM UTC
Finalized: 4/7/2020 5:49:30 PM UTC
STAT Request: 0

Findings
A non-contrast CT of the patient was obtained in sternal recumbency and is available for review in DICOM format of patient ID. Series obtained include transverse soft tissue (smooth reconstruction kernel) and bone (sharp reconstruction kernel) algorithm images using 1.25mm slice thickness.

Total images: 708
Body parts evaluated: Whole patient
Physical length of study: 20.5 cm

The osseous structures of the skull are unremarkable. The cervical vertebrae are appropriately aligned. The thoracic subcarapacial vertebral bodies are appropriately aligned; there is no effacement of the vertebral canal. The humeral diaphyses are unremarkable. The radial and ulnar diaphyses are unremarkable bilaterally. The carpal bones, metacarpal bones, and phalanges are unremarkable. The distal diaphyses are unremarkable. The tibial and fibular diaphyses are unremarkable. The tarsal bones, metatarsal bones, and phalanges are unremarkable. There is a metal transponder within the left inguinal region. There is mild asymmetry and deformation of the shape of the carapace; there is an indentation of the right carapace. The plastron is unremarkable. The trachea is unremarkable with smooth mucosal margins. The left principal bronchus is unremarkable. The right principal bronchus is unremarkable. The left pulmonary parenchyma is unremarkable. The right pulmonary parenchyma is unremarkable. The left pulmonary parenchyma extends across midline to the right. There is a discrete distinction of the left pulmonary interstitium and the vascular nature is effaced by the soft tissue.

Abnormal buoyancy. No inflation to R lung.

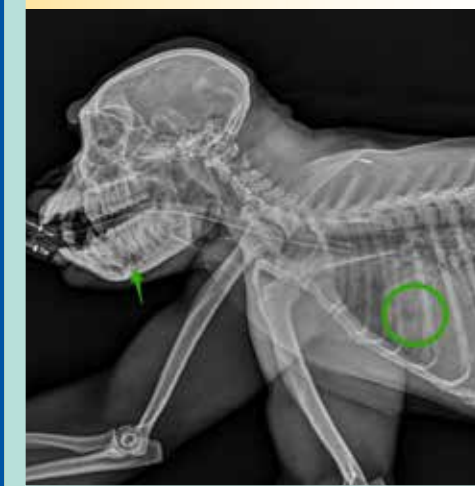
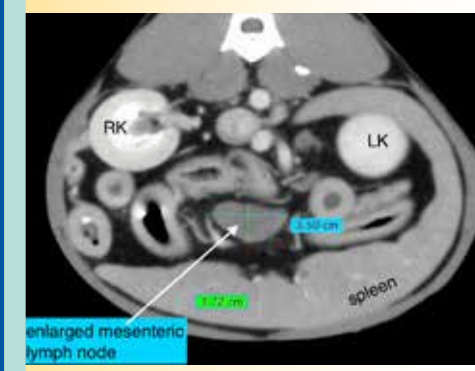
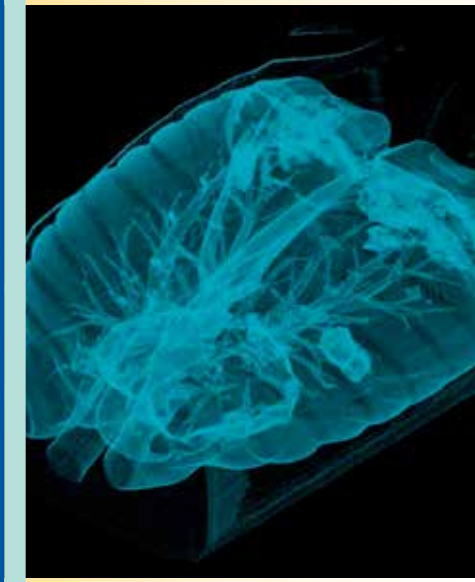
Sample Reports Available at CZS.org/Radiology

The mission of the Chicago Zoological Society's Veterinary Services Department is to provide a visionary level of veterinary care to our patients, to inspire people of all backgrounds, and to passionately advance the professional standards for zoological medicine in a way that positively impacts the conservation of wildlife and nature. The department's current programs focus on three core areas of strength: medical imaging, anesthesia and analgesia, and veterinary education.

For More Information Please Visit CZS.Org/Radiology
Radiology@CZS.Org / 708-688-8727

Chicago Zoological Society

RADIOLOGY CONSULTING SERVICE

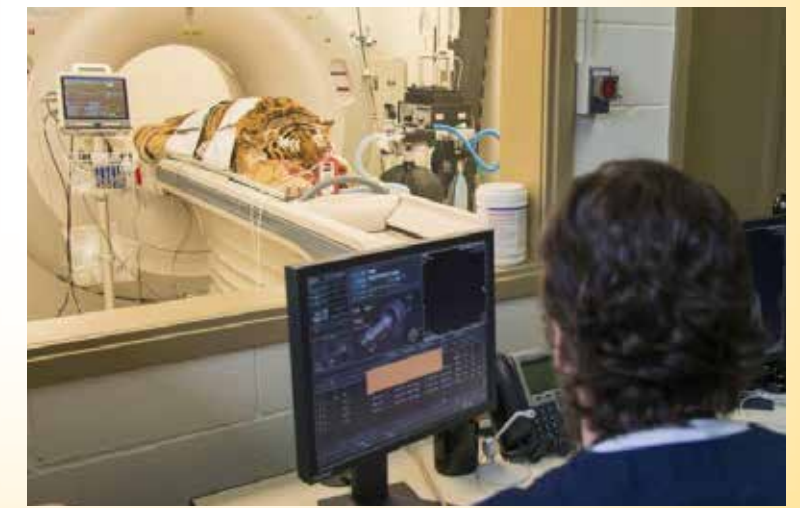

The Chicago Zoological Society Radiology Consulting Service is dedicated to aiding veterinarians around the world in providing the most advanced medical care for zoo and aquarium animals, pioneering advancements in diagnostic medical imaging, and helping conservation programs succeed.

Advances in diagnostic imaging technology have dramatically improved the quality of medicine available to zoological species. Imaging modalities and techniques that were unimaginable only a few decades ago are now components of everyday care. Veterinarians are increasingly challenged to remain experts in all species and disciplines.



ACVR board-certified veterinary radiologists provide the most accurate and complete interpretation of medical imaging studies.



The expertise and high-quality service they provide allow for clinical veterinarians to best define a diagnosis and develop an effective treatment plan. To date, veterinary radiologists have focused largely on domestic animals, resulting in a limited understanding of imaging in many zoo species. **We are leading the way in changing this.**

Meet Our Radiologists

Eric T. Hostnik, DVM, MS, DACVR, DACVR-EDI is a highly skilled radiologist with very strong interests in diagnostic imaging of zoo and aquarium species. He is a founding member and current president Zoo, Exotic, Wildlife Diagnostic Imaging Society within the American College of Veterinary Radiology. Dr. Hostnik has been reading cases for the CZS Radiology Consulting Service for several years, supporting the diagnostic imaging needs of our clients around the world.

Dr. Hostnik completed his diagnostic imaging residency and Master's degree program at the Ohio State University, where he is currently on faculty as an assistant professor. He completed his veterinary education at the University of Florida, followed by additional training as an emergency clinician with companion animals and pocket pets at VCA South Shore Animal Hospital. His research interests focus on the use of CT, including the role of CT in zoo settings.

When not working, Dr. Hostnik enjoys the music and sports of Columbus, Ohio, as well as snowboarding and camping when home in Vermont.



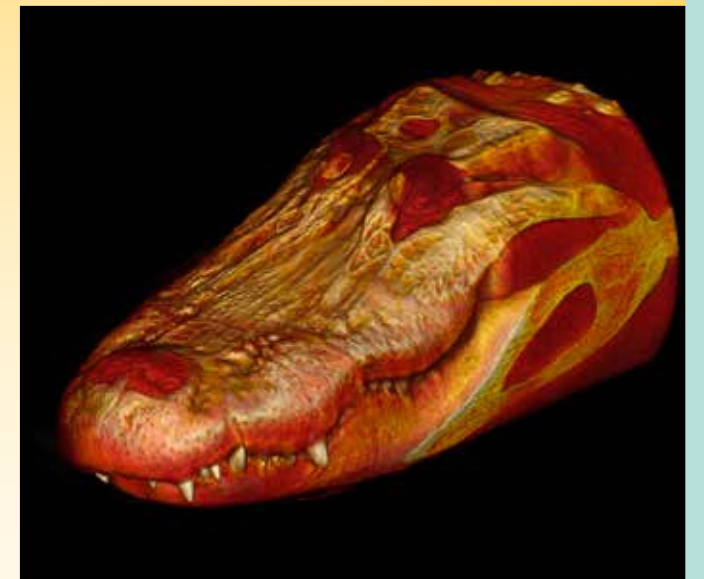Philip (PJ) Hamel, DVM, MPH, DACVR is the latest addition to our RCS team. Dr. Hamel completed a radiology residency at the University of Florida and is a Diplomate of the ACVR. Dr. Hamel now works at a specialty hospital in British Columbia, and maintains a long-standing personal and professional commitment to radiology of non-domestic species. He is particularly interested in the role diagnostic imaging can play in wildlife health assessments and conservation.

Originally from coastal Massachusetts, Dr. Hamel is drawn to the ocean to pursue many water related hobbies including paddling, scuba diving, and sailing.



Confidentiality Matters

We understand the sensitive nature of your medical images and case information. All submitted cases are anonymized of identifying patient data prior to storage in archival databases. Electronic security measures are in place to eliminate third-party access. DICOM medical image files can be submitted directly to our server. All case information and consultation reports are delivered through a dedicated web-based software interface with a log-in unique to your institution.



Collaborative Advice from the CZS Team

The CZS Veterinary Services Department works as a team. Collaborative input on submitted radiology cases is always available, if requested, at no additional cost.

The CZS team includes veterinarians with advanced training in zoological medicine, anesthesia, reproductive services, epidemiology, and wildlife disease. With decades of collective experience, our team is always happy to provide input beyond diagnostic imaging.

Brookfield Zoo is also home to the most comprehensive and advanced imaging suite dedicated to zoo animals, including a 90cm large bore CT scanner with a large animal table that can accommodate the largest zoo patients. CZS has also established a database of diagnostic images available for comparative and reference purposes.

